

Treatment of Severe Allergic Conjunctivitis with AK002 Indicated Improvement of Ocular Signs and Symptoms and Reduction of Severity of Comorbid Atopic Diseases in a Phase 1b Open-Label Study

Andrea Leonardi¹; Stephen D. Anesi²; Peter Y. Chang²;
Andrea M. Kantor³; Alan T. Chang³; Henrik S. Rasmussen³;
C. Stephen Foster²

¹University of Padova, Padova, Italy; ²Massachusetts Eye Research & Surgery Institution, Waltham, MA;
³Allakos, Inc., Redwood City, CA

EAACI 2020
London, UK June 6th-8th 2020

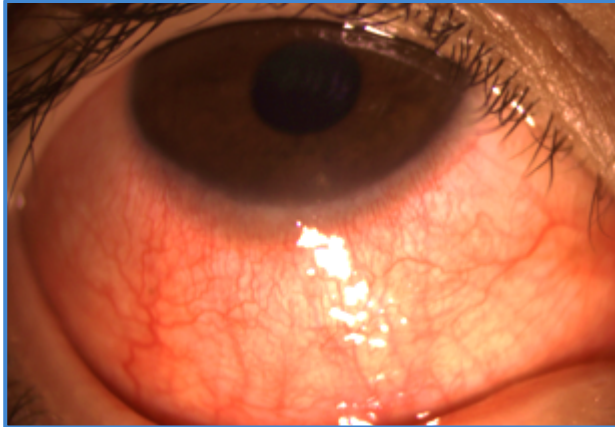
Disclosures

- No financial conflicts to disclose
- AK002 is an investigational drug in clinical development as is not FDA or EMA approved

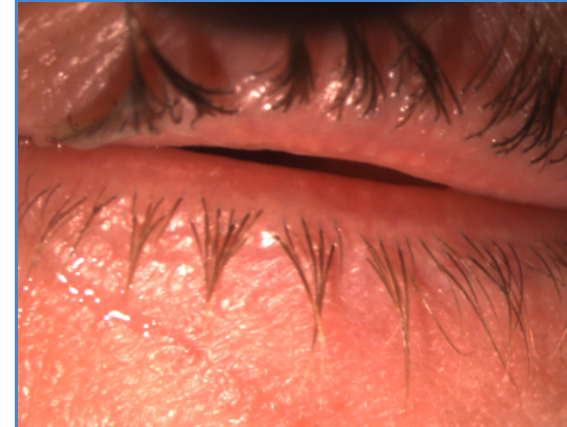AKC, PAC, & VKC Are Severe and Chronic Forms of Allergic Conjunctivitis

	CLINICAL FEATURES	IMPACT
Symptoms	Extreme Itching, Photophobia, Pain, Sensation of Foreign Body, Burning, Watering, Mucous Discharge	Poor Quality of Life
Signs	Redness (Hyperemia), Swelling (Chemosis, Periorbital Edema), Tarsal Papillae, Cicatricial Changes, Corneal Damage (Keratitis, Epithelial Erosion, Ulcers)	Vision Loss, Poor Quality of Life
Atopic Comorbidities	Common Atopic Comorbidities Include Atopic Dermatitis, Asthma, and Rhinitis	High Systemic Disease Burden, Poor Quality of Life

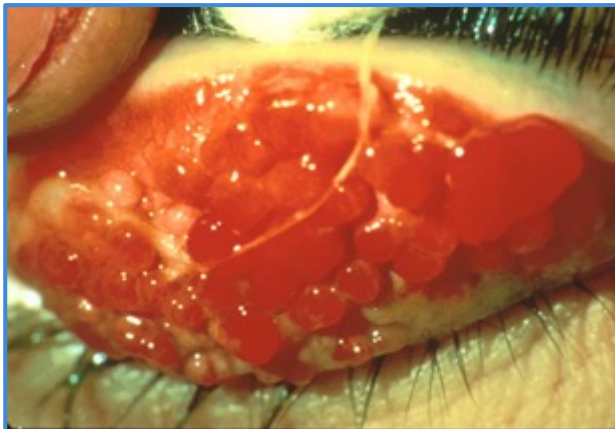
Severe Allergic Conjunctivitis



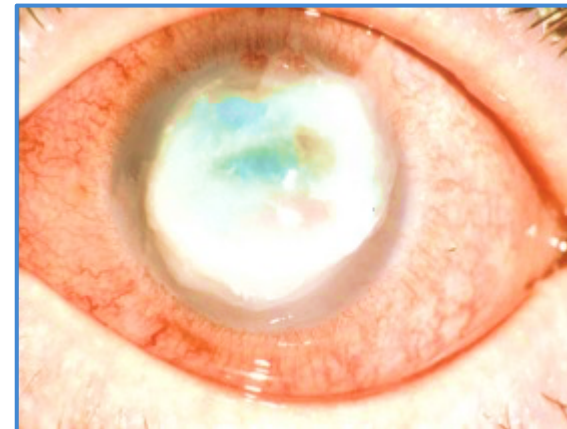
**Redness,
Chemosis**



**Photophobia,
Watering,
Periorbital
Swelling**



**Giant
Papillae**

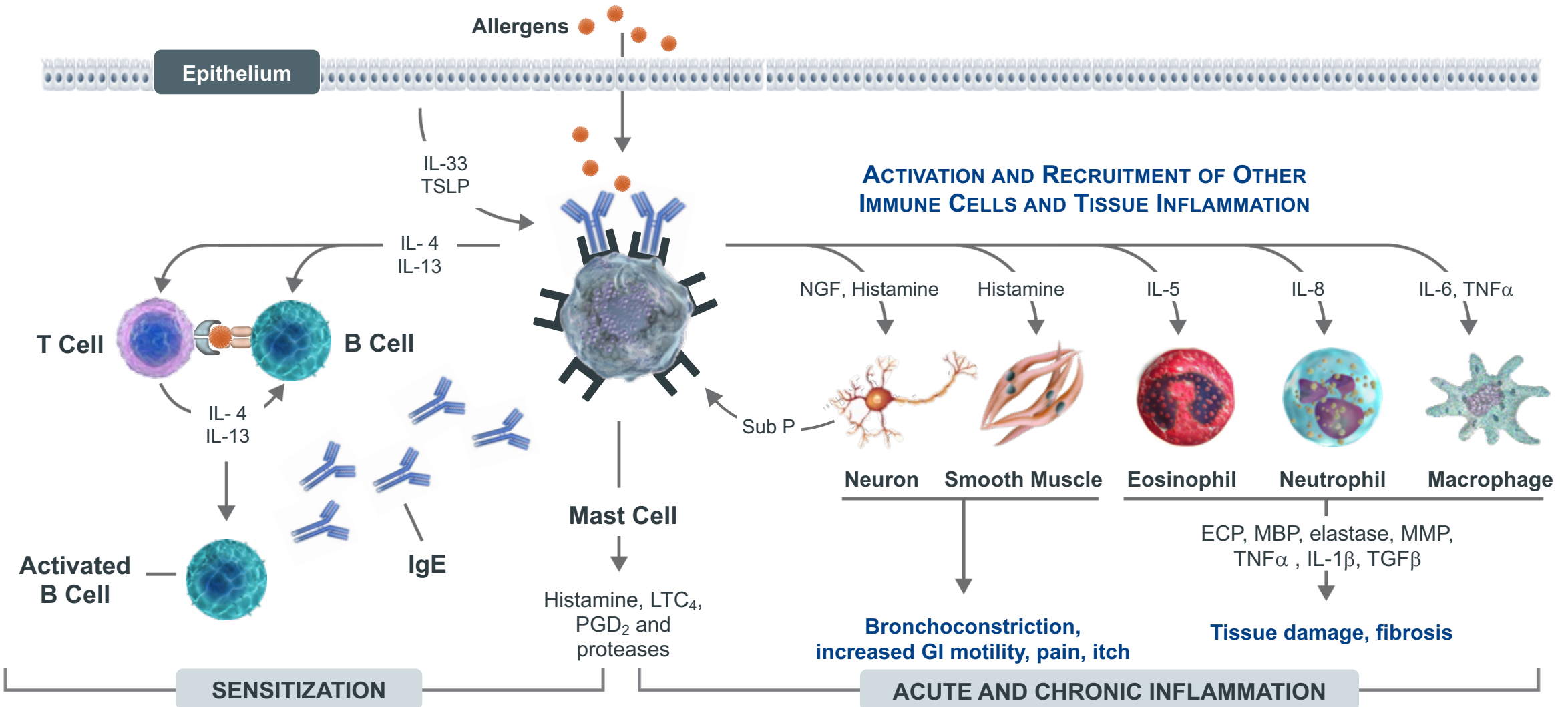


**Corneal
Ulcer
(Vision Loss)**

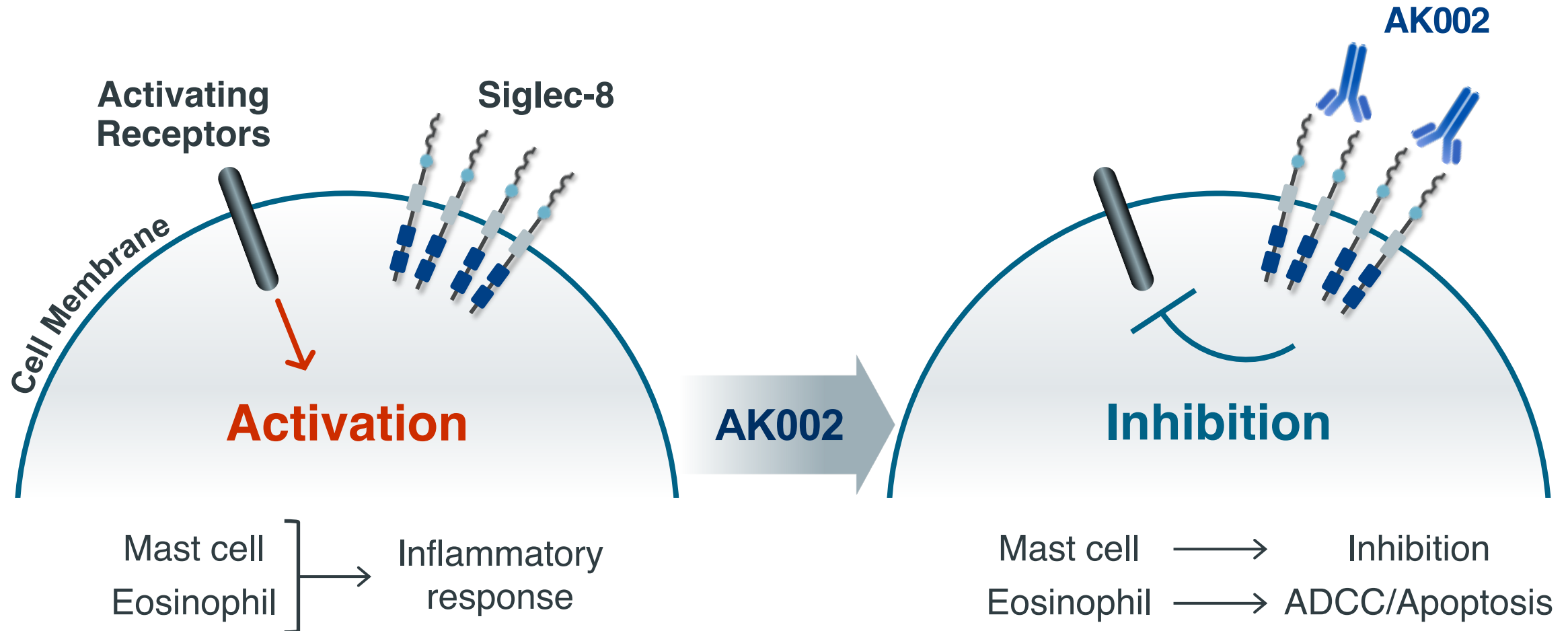
Mast Cells and Eosinophils are Key Effector Cells in Allergic Conjunctivitis

	Perennial Allergic Conjunctivitis (PAC)	Vernal Keratoconjunctivitis (VKC)	Atopic Keratoconjunctivitis (AKC)
Mast Cells	+++	+++	++
Eosinophils	++	++	+++
T and B cells	+	++	+++
Fibroblasts		++	++

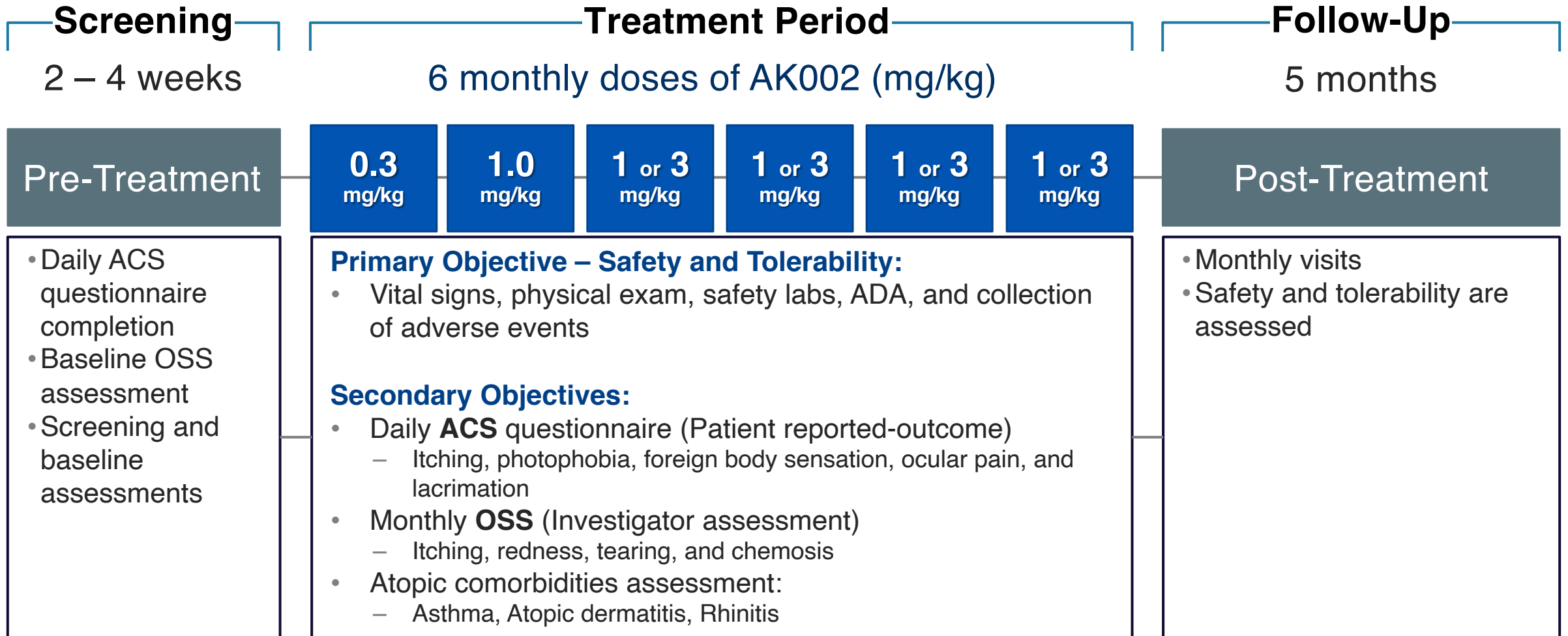
Mast Cells and Eosinophils Are Key Drivers of Inflammatory Disease



AK002 Targets Siglec-8 on Eosinophils and Mast Cells



KRONOS: Phase 1b Study



AK002 Clinical Activity Measured by PRO & Investigator Assessments

ALLERGIC CONJUNCTIVITIS SYMPTOM (ACS)

- **Daily patient questionnaire**
- Total ACS (0 – 50 point scale):
 - Itching (0-10)
 - Light sensitivity (0-10)
 - Eye pain (0-10)
 - Foreign body sensation (0-10)
 - Watering eyes (0-10)

OCULAR SYMPTOM SCORE (OSS)

- **Monthly investigator assessment**
- Total OSS (0 – 13 point scale):
 - Itching (0-4)
 - Redness (0-3)
 - Tearing (0-3)
 - Chemosis (0-3)

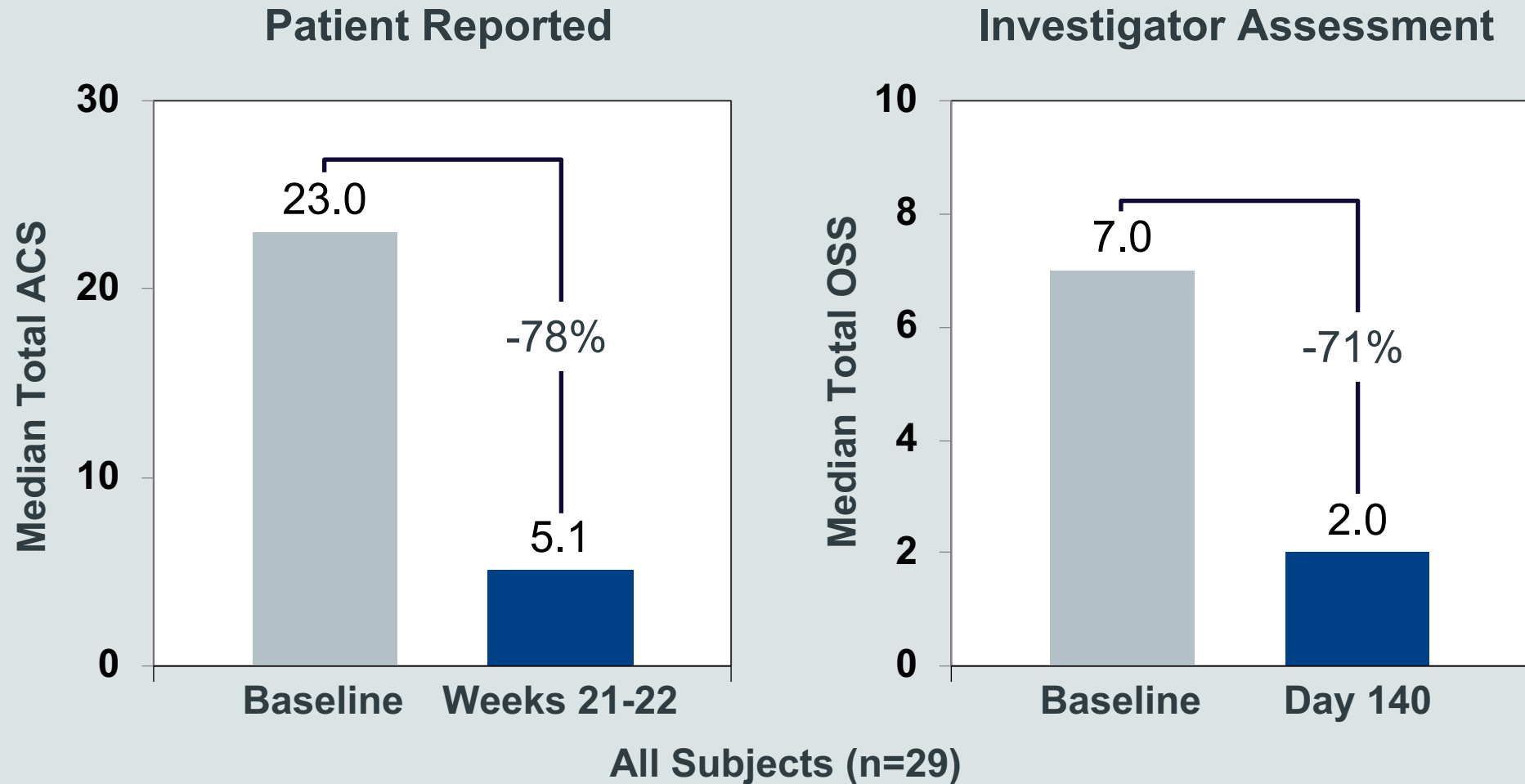
COMORBID ATOPIC DISEASE ASSESSMENTS

- **Daily patient questionnaire** for patients with comorbid atopic dermatitis, asthma and/or rhinitis
- 0 – 10 point scale grading global disease severity

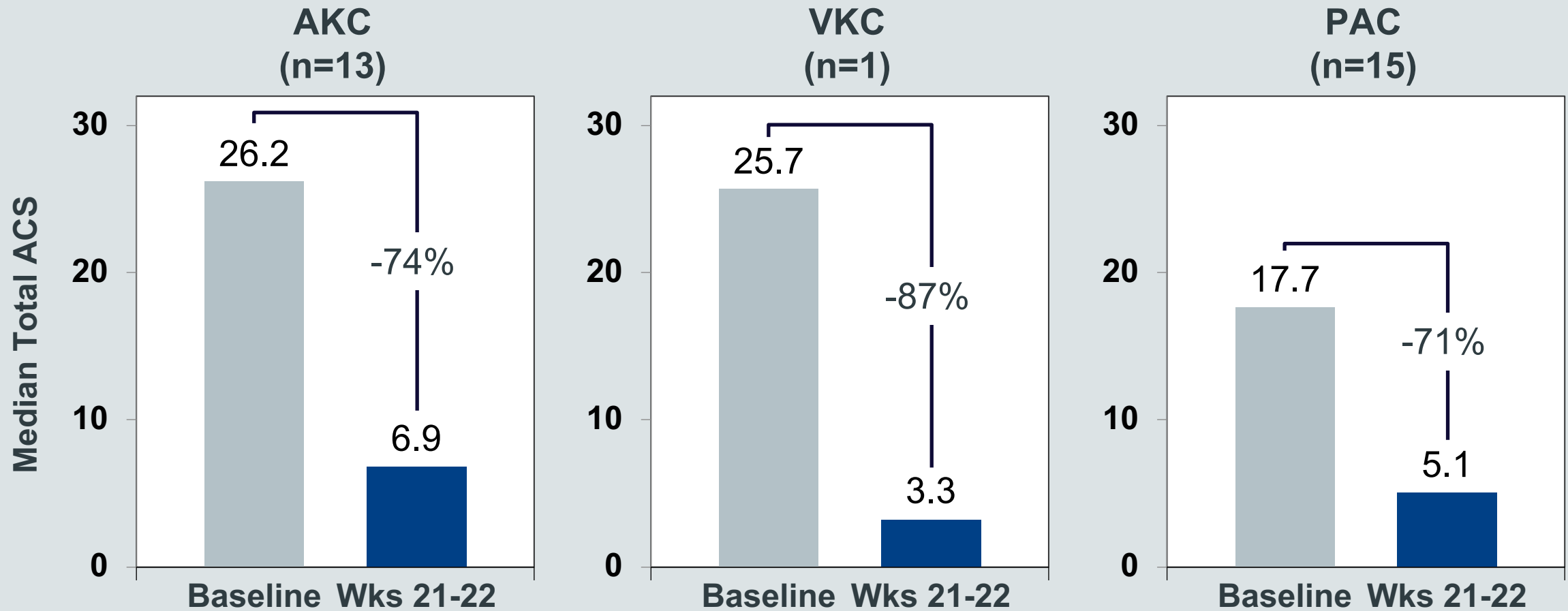
Baseline Characteristics

		AKC (N=13)	VKC (N=1)	PAC (N=15)	Total (N=29)
Age, Median (Range)		50 (23-72)	25	53 (29-66)	51 (23-72)
Female		38%	0	67%	52%
Weight (kg), Median (Range)		81 (50-107)	68	84 (52-108)	81 (50-108)
BMI (kg/m ²), Median (Range)		26 (20-43)	21	29 (19-40)	27 (19-43)
Total Symptom Score ¹	ACS, Median	26.2	25.7	17.7	23.0
	OSS, Median	7.0	7.0	6.0	7.0
Atopic Comorbidities by Medical History	≥1 Comorbidity	85%	100%	87%	86%
	Atopic Dermatitis	85%	0	40%	59%
	Asthma	54%	100%	27%	41%
	Rhinitis	54%	100%	73%	66%

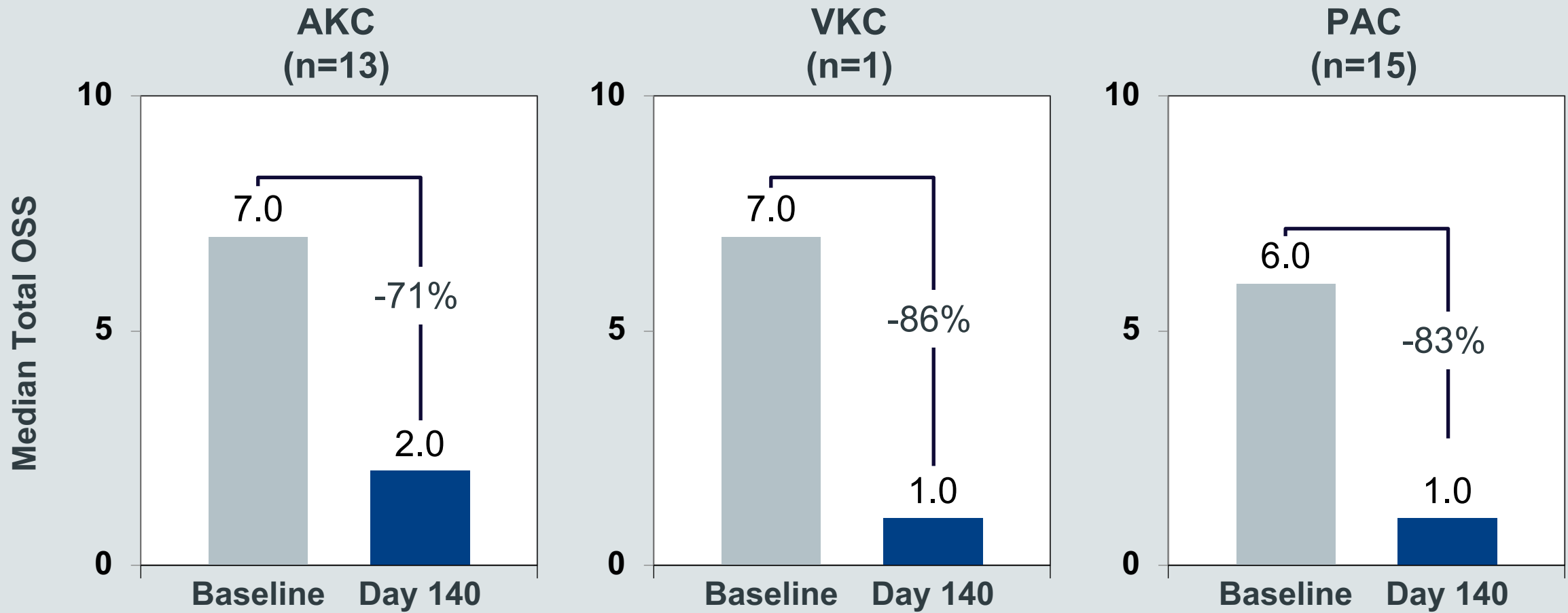
Improvements in Allergic Conjunctivitis Signs & Symptoms



Patient Reported Improvements in Multiple Forms of Severe AC



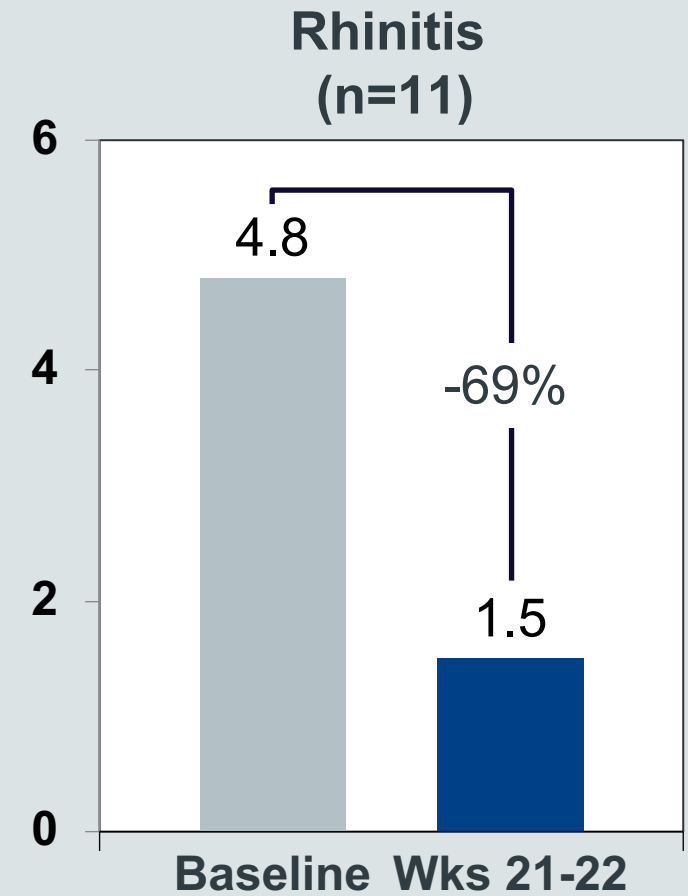
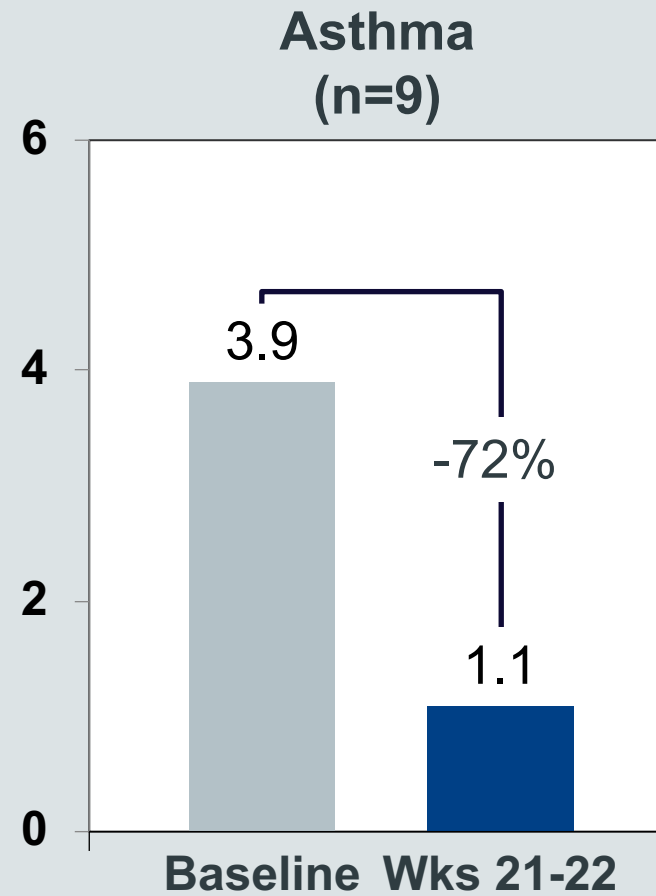
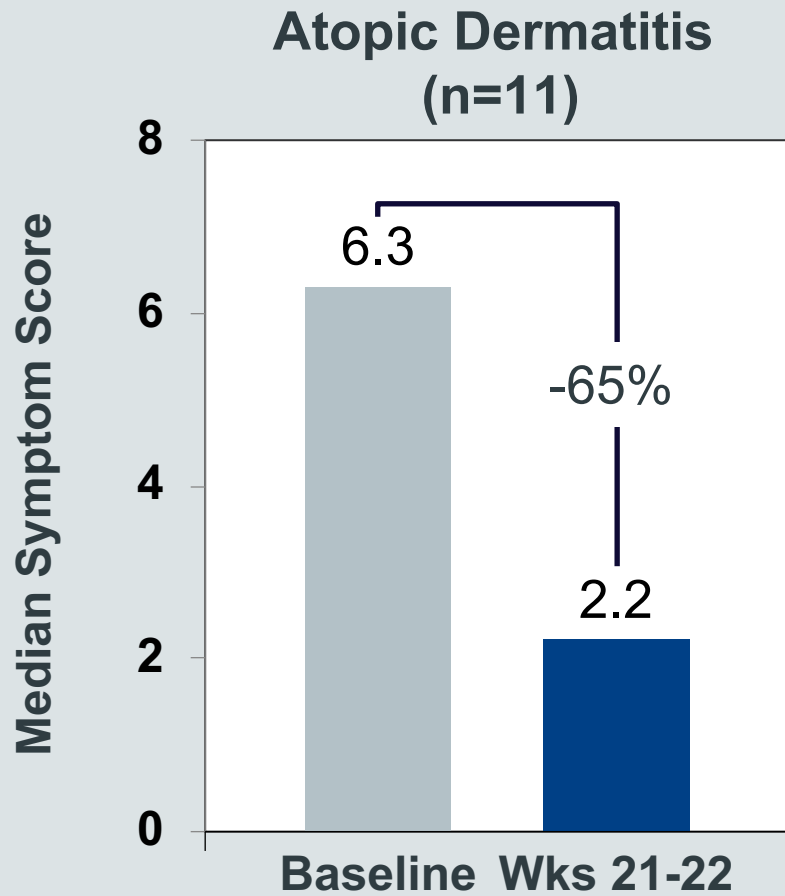
Physician Assessed Improvements in Multiple Forms of Severe AC



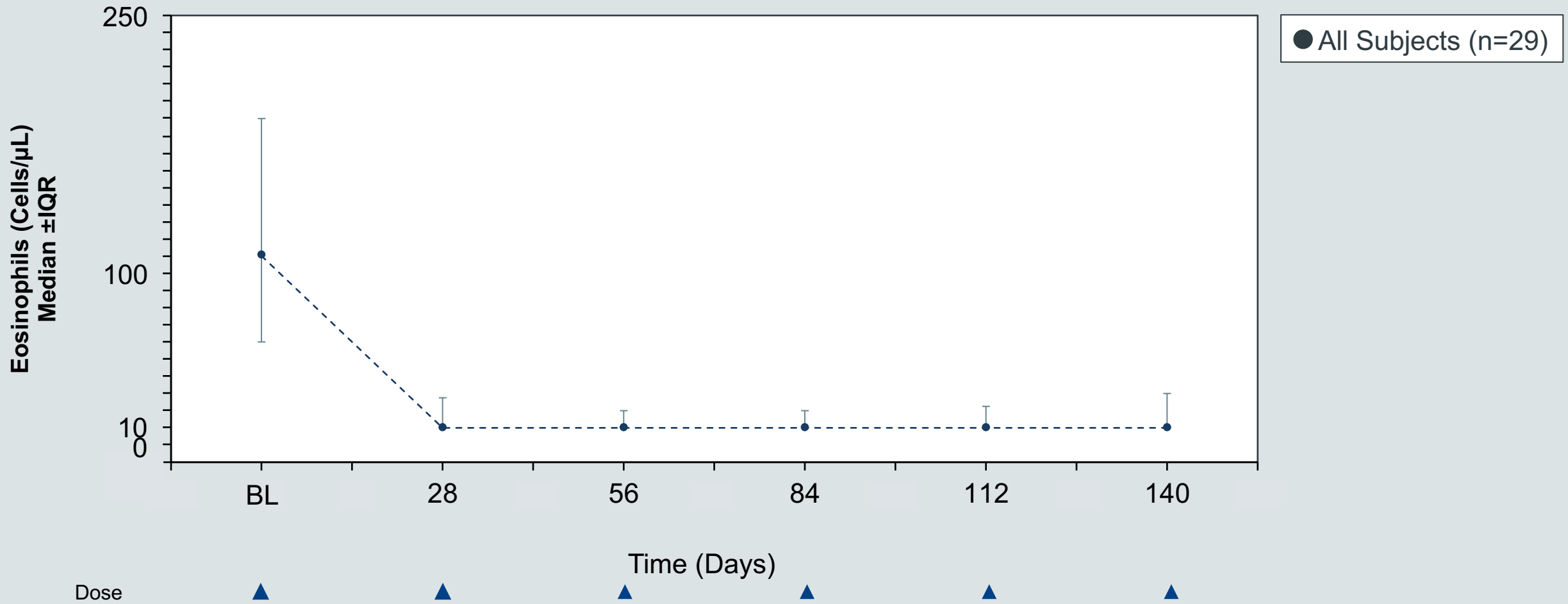
Consistent Improvements Across Signs & Symptoms

	Symptom	Median % Δ from BL to Wk 21-22
Allergic Conjunctivitis Symptom (ACS) Patient Reported - Daily	Itching	-74%
	Light Sensitivity	-57%
	Eye Pain	-75%
	Foreign Body Sensation	-80%
	Watering Eyes	-76%
	Symptoms & Signs	Median % Δ from BL to Day 140
Ocular Symptom Score (OSS) Investigator Assessment - Monthly	Itching	-67%
	Redness	-67%
	Tearing	-50%
	Chemosis	-100%

Substantial Improvement in Atopic Comorbidities



Absolute Blood Eosinophil Counts



Safety Summary

- Generally well-tolerated
- No drug-related Serious Adverse Events
- Most common adverse event was mild to moderate infusion-related reactions (IRRs; flushing, feeling of warmth, headache, nausea, or dizziness)

Case Study 1: Reversal of Neovascular and Inflammatory Changes

AKC with Comorbid Atopic Dermatitis & Rhinitis

Demographics

- 27 year-old male with severe AKC, atopic dermatitis, and rhinitis
- Baseline normal peripheral blood eosinophils (190 eos/ μ L)

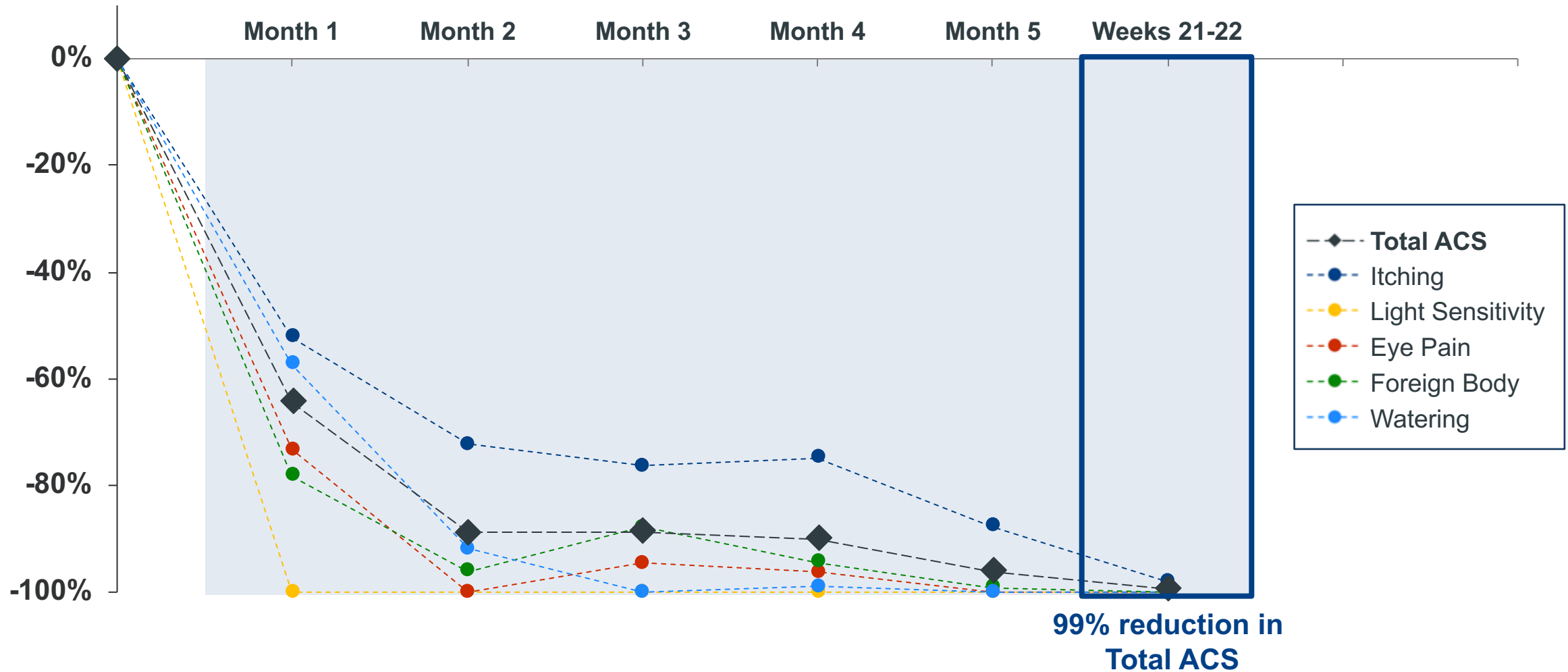
Symptoms

- Itching, foreign body sensation, and watering
- Hyperemia (redness) and palpebral papillae
- Moderate comorbid atopic dermatitis & rhinitis

Treatment History

- AKC: topical antihistamines, topical corticosteroids
- Atopic Dermatitis: oral antihistamines
- Rhinitis: oral antihistamines

Case Study 1: Resolution of Ocular Symptoms

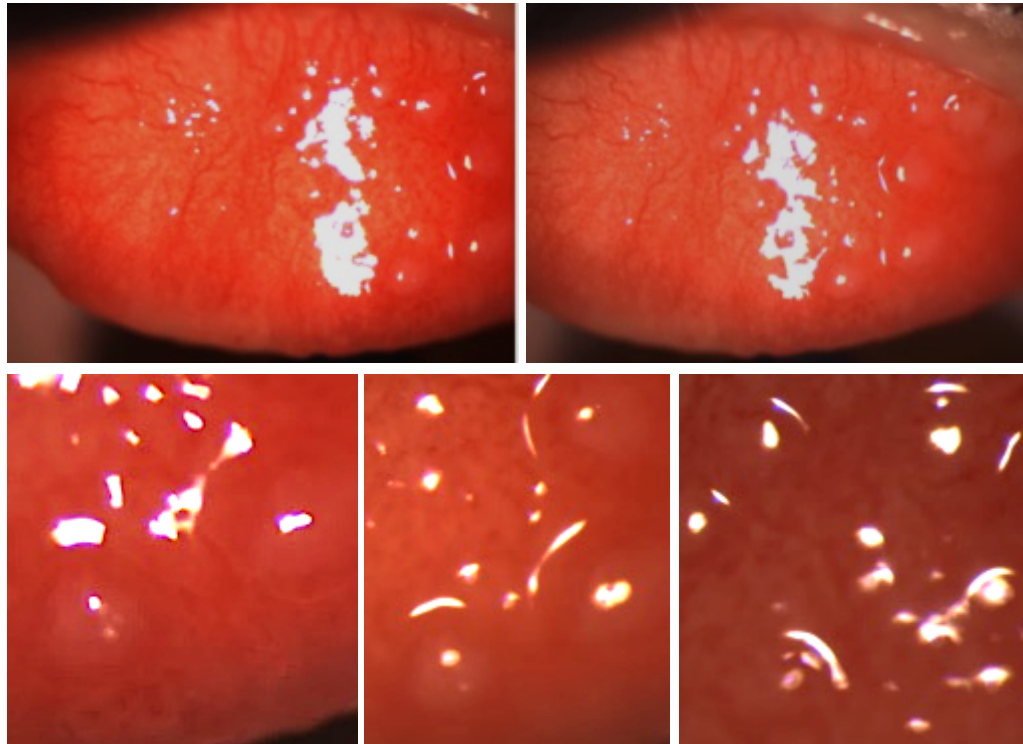


Case Study 1: Reversal of Neovascular and Inflammatory Changes

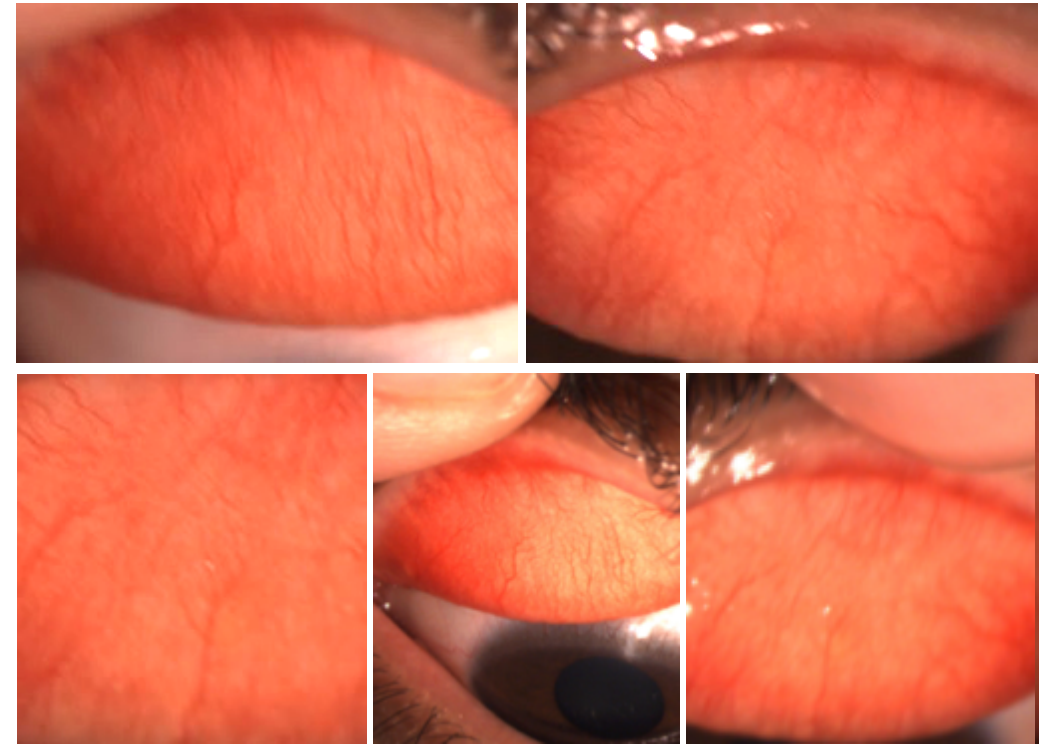
Prior to AK002

After 3 Doses of AK002

Upper tarsal papillae



Resolution of papillae



Case Study 2: Improvement in AKC and Atopic Comorbidities

AKC with Comorbid Atopic Dermatitis, Asthma & Rhinitis

Demographics

- 53 year-old male with AKC, atopic dermatitis, asthma, and rhinitis
- Baseline normal peripheral blood eosinophils (120 eos/ μ L)

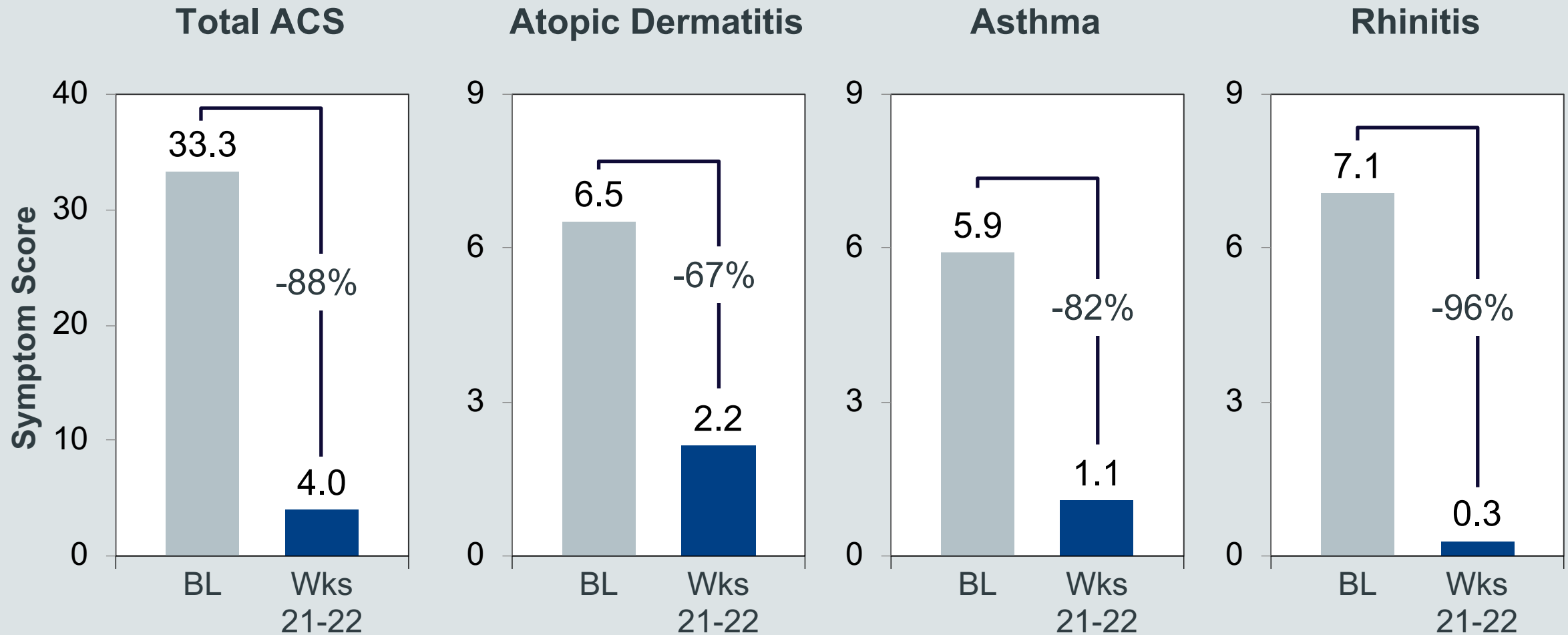
Symptoms

- Itching, photophobia, foreign body sensation, redness, & chemosis
- Severe comorbid atopic dermatitis & asthma

Treatment History

- AKC: topical antihistamines, topical corticosteroids
- Atopic Dermatitis: dupilumab, topical corticosteroids
- Asthma: daily ICS/LABA, albuterol
- Rhinitis: oral antihistamines

Case Study 2: Improvements in Ocular Signs and Symptoms and Comorbid Atopic Dermatitis, Asthma, and Rhinitis



Conclusions/Discussion

- Mast cells and eosinophils are key effector cells in the pathogenesis and perpetuation of allergic conjunctivitis
- AK002 is a novel anti-Siglec-8 antibody that has demonstrated selective and rapid depletion of eosinophils and inhibition of mast cells in preclinical and clinical studies
- Substantial and consistent improvements reported in symptoms by patients and investigators in multiple forms of severe AC
- Clinical activity observed in atopic comorbidities
- AK002 was generally well-tolerated
- AK002 may be a promising treatment for severe AC as well as atopic dermatitis, asthma and other atopic conditions

Thank you

